

# The Application of Forensic Imaging to Sex Estimation: Focus on Skull and Pelvic Structures

Min Zhang<sup>1,2,\*</sup>

<sup>1</sup> Department of Criminal Justice, Coppin State University, MD 21216, USA

<sup>2</sup> Present/Permanent Address: 2500 W. North Avenue, Baltimore, MD 21216, USA

\* Corresponding author. E-mail: mzhang@coppin.edu (M.Z.)

Received: 18 April 2024; Accepted: 14 May 2024; Available online: 16 May 2024

**ABSTRACT:** Forensic imaging is recognized as a vital tool in forensic practice mostly reflected by the wide use of post-mortem imaging in death investigations. With the surge of forensic imaging applications and research in recent years, many forensic subdisciplines have adopted this tool as a scientific investigation method, including forensic anthropology. Sex estimation is one of the key assignments in forensic anthropology along with age, ancestry and stature estimation. Traditionally, this assignment is done with non-metric macroscopic examination and metric analysis performed by forensic anthropologists. Today, forensic imaging serves as an auxiliary tool that adds to traditional methods and brings sex estimation to a dynamic era. The purpose of this article is to review forensic imaging methods in forensic anthropology sex estimation with a focus on skull and pelvic structures, aiming to provide insights into the best practices and prospective research directions.

**Keywords:** Forensic imaging; Forensic anthropology; Macroscopic examination; Metric analysis; Sex estimation



© 2024 by the authors; licensee SCIEPublish, SCISCAN co. Ltd. This article is an open access article distributed under the CC BY license (<http://creativecommons.org/licenses/by/4.0/>).

## 1. Introduction

Forensic imaging is the use of images to explain and document findings for forensic and medico-legal purposes. The various methods of forensic imaging mainly include X-ray, computed tomography (CT), magnetic resonance imaging (MRI), augmented minimally invasive techniques through CT and MRI such as angiography and biopsy, and three-dimensional (3D) surface scanning, as an adjunct or alternative to the traditional invasive autopsy [1,2]. In recent years, post-mortem imaging has been widely used in death investigations [3], indicating forensic imaging is a method of choice in practice. With the surge of forensic imaging applications and research, many forensic subdisciplines have adopted it as a scientific investigation method, including forensic anthropology [4].

Forensic anthropology examines human remains or other conditioned bones and tissues to estimate the biological profile comprising sex, age, stature and ancestry of unknowns, estimate postmortem interval (PMI) and provide opinions regarding the circumstances surrounding death [5,6]. As an essential part of forensic anthropology casework, sex estimation requires foremost consideration in the examination of skeletal remains [7]. Traditionally, forensic anthropologists conduct non-metric macroscopic examination and metric analysis on the skull, pelvic, or other skeletal structures to undertake this task. The current practice of the *Standard for Sex Estimation in Forensic Anthropology* (ANSI/ASB Standard 090) [8] also emphasizes a morphologically-based or mathematically-based scientific manner for estimating sex. While there is evidence that the pelvis is the most accurate skeletal region for estimating sex, most forensic and biological anthropologists will also use skull traits to complement pelvic indicators, or in situations where the pelvis is unavailable for analysis or gives confusing signals [9]. Given the popularity of forensic imaging in scientific investigations, there has been growth in the application of forensic imaging, especially CT imaging to sex estimation [10]. However, the role of forensic imaging in sex estimation has not been fully revealed probably due to the variety of methods, the complexity of the skeletal traits, and other reasons such as the unique working conditions of specific imaging methods. Additionally, the ANSI/ASB Standard 090 does not include any forensic imaging methods. To shed light on best practices and prospective research directions, it is imperative to give an overview of the role of forensic imaging and discuss its advantages, limitations and potential in sex estimation.

## 2. Methods

A detailed search of imaging method applications to forensic sex estimation was conducted through Google Scholar, PubMed Central®, and Elsevier ScienceDirect® databases for the 10 years prior to April 2024. The search was carried out by entering the keywords “X-ray/CT/MRI /surface scanning/ultrasound”, “sex estimation”, and “skull/pelvis”. Exclusion criteria were as follows: articles not written in English; articles referring to sex estimation on the other structures other than the skull or pelvis; articles not referring to X-ray, CT, MRI, surface scanning, or ultrasound imaging methods; and articles referring to other biological profile estimations but not sex estimation except skull surface scanning-related articles because there was no sex estimation specific skull surface scanning reported. After a primary screening followed the exclusion criteria, a secondary selection was conducted to exclude articles repetitively referring to the same imaging methods that have been well-reported in other studies. Then, the remaining research articles on the subject were collected, analyzed and descriptively outlined as in Results. Several studies on pelvic and skull traits published before 2014 were cited to help with the concept understanding of this review. A variety of relevant articles were referred to support the review findings and discussion. The online open tool Sketchfab [11] was used to indicate skull and pelvic morphological traits.

## 3. Results

### 3.1. X-Ray and Sex Estimation

Radiographic images were measured using KLONK image measurement software tool with linear, angular measurement to estimate sex based on gonial angle, width, and breadth of the ramus of the mandible; it was found that the best parameters of sex dimorphism were coronoid height, condylar height, and projective height of ramus, and breadth measurements were not significant dimorphic in the studied Indian population [12]. By using ImageJ5 software®, foramen magnum length and bizygomatic breadth were selected among 5 variables along with maximum cranial base length, maximum cranial breadth and foramen magnum breadth by discriminant function procedure; the results showed the precision was between 86.4% and 88.6% in the determination of sex, with the accuracy of 85.7% to male and 87.2% to female in contemporary Colombian population [13]. While glabella is considered to be a promising trait in non-metric sex estimation, nasion-sella-glabella (NSG), sella-glabella-nasion (SGN), and glabella-nasion-sella (GNS) angles on lateral cephalograms as an angular metric analysis method for sex estimation has received attention. By measuring these angles in the Indonesian group, the results showed that male adults had smaller NSG and SGN angles but a bigger GNS angle than female adults [14]. In a cross-sectional and descriptive-analytic study to determine the anthropometric characteristics of ilium for sex estimation in 180 Iranian population, the highest accuracy for sex estimation was related to the height of ilium with an accuracy of 77% [15]. Through textual analysis of pelvic radiographs, a set of textural features of the identified fourteen distinct regions of interest were calculated by using pyRadiomics in Python and the results suggested the femoral neck and ischium regions exhibited distinctive characteristics between sexes [16].

### 3.2. CT and Sex Estimation

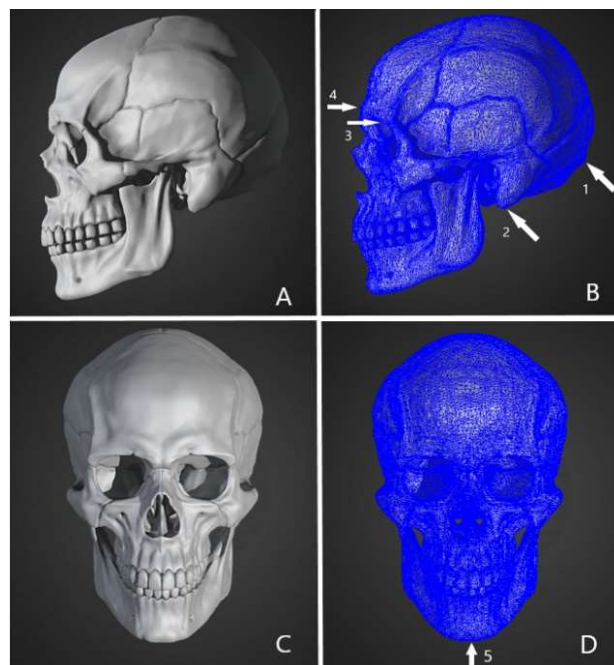
#### 3.2.1. Sex Estimation Based on Skull Structure CT Imaging

In the non-metric macroscopic examination, 5 skull traits nuchal crest, mastoid process, supra-orbital margin, supra-orbital ridge/glabella, and mental eminence are observed from lateral and frontal views (Figure 1) to study sexual dimorphism. A study [17] demonstrated that 3D modeling of volumetric cranial CT images had a strong ability to estimate sex based on the same 5 skull traits scoring system, with over 98% accuracy in the estimation of males and the glabella as the most effective morphological trait. Four morphometric traits (Figure 1B) were studied by a fully automatic algorithm applied on 3D models and further processed by computer vision and machine learning algorithms; the sex estimation results yielded correct classification performance over 91% for the entire selected 156 Greek samples [18]. A similar study has been done in Turkey; the results showed that the most significant sexual dimorphism was observed in the glabella and the nuchal crest was considered not as significant as other traits [19].

In skull metric analysis, it is recommended to locate the landmarks and take measurements between landmarks [20] to study sexual dimorphism. Morphometry of the mandibular was measured via CT imaging by measuring the angles to estimate sex, the results showed the accuracy was 67%, with 66.7% in males and 67.3% in females [21]. A study revealed that a complete mandible metric analysis by CT imaging had the correct classification rate of 90.8% and a cross-validation accuracy of 89%, the incomplete mandible metric analysis's correct classification and cross-validation

accuracy rates were much lower [22]. Some CT imaging studies have demonstrated effective skull metric analyses by measuring the distances between different landmarks. Existing CT images of Tunisians were analyzed by ASIR™ software in a General Electric™ workstation to provide reference sex estimation data in the population. By placing 37 landmarks on 3D CT skull images, 27 inter-landmark distances were defined. Results showed that male values were greater than female in all measurements; a six-variable model produced 85.9% sexing accuracy with  $-0.97\%$  sex bias, and a nine-variable model reached the maximum classification accuracy of 90% with  $-2.9\%$  sex bias were established as population-specific reference data [23]. CT imaging measuring methods were also used in establishing specific craniofacial reference parameters in the Brazilian [24], Gujarati [25], Turkish [26] and other populations [27,28]. The results all suggested the population-specific sexual dimorphic parameters, such as mastoid process showed good sexual dimorphism in Brazilian skulls; a combination of maximum cranial length, bimaxillary breadth and morphological facial height provided an accuracy of 88.7% in the Gujarati population. An innovative approach utilized cranial CT scans from the French [29] and Czech [30] populations to test sex estimation from exocranial meshes based on the form and shape color scale analyses; the result suggested the accuracy rate in form analysis exceeded 90% and the accuracy rate in shape analysis was around 80%. The reliability of the exocranial meshes method was tested on contemporary and ancient Egypt populations, the contemporary Egypt sex estimation accuracy was almost 90% for form and shape but ancient Egypt sex estimation showed the accuracy rate was lower than 70% [31]. The convolutional neural networks (CNN) were established to learn the sexual dimorphism of skulls by being trained on images that were virtually reconstructed from hospital CT scans [32] and postmortem CT images [33]; the established CNN by hospital images showed 95% accuracy, whereas the postmortem CT images generated CNN showed 93% accuracy in sex estimation.

Regardless of the population-specific sexual dimorphism, some studies pointed out the population-inclusive sex estimation possibilities from skull CT scans. The non-metric 5 skull traits were studied in Asian groups including Japanese, Thai, and Filipino individuals [34]; the statistical models did not yield any significant results when the populations were included, and the univariate and multivariate models' efficacy on the Filipino sample indicated that they could be applied to other East and Southeast Asian populations. A study [35] found that in situations where ancestry was not determined, population-inclusive assigned-sex estimation models can be utilized in place of population-specific models by combining metric and non-metric methods.

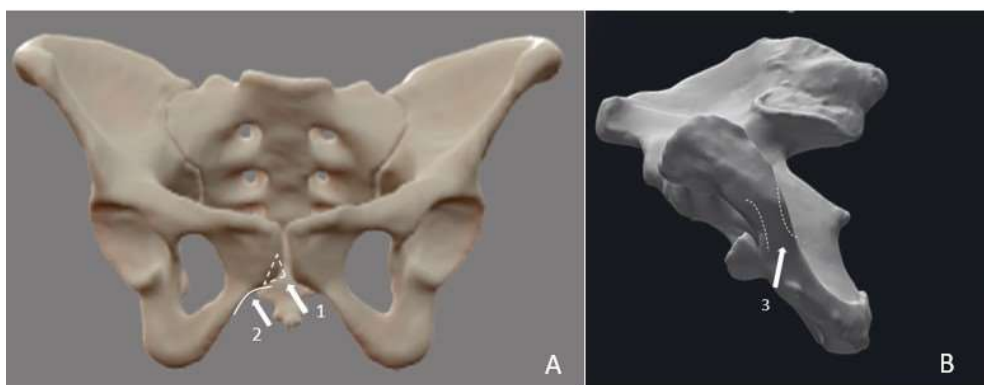


**Figure 1.** Simulated human skull 3D reconstruction in lateral and anterior views with highlighted five sexual traits. (A) lateral view of simulated human skull 3D reconstruction. (B) blue wireframe of A with four traits; arrow 1 indicates Nuchal Crest; arrow 2 indicates Mastoid Process; arrow 3 indicates Supra-Orbital Margin; arrow 4 indicates Supra-Orbital Ridge/Glabella. (C) Anterior view of simulated human skull 3D reconstruction. (D) blue wireframe of C with Mental Eminence trait (arrow 5). The simulation was generated by using Sketchfab software. Original 3D model credits: Ruslan Gadzhiv.

### 3.2.2. Sex Estimation Based on Pelvic Structure CT Imaging

Ventral arc (VA), subpubic contour (SC), and the medial aspect (MA) of the ischiopubic ramus (Figure 2) have been considered to be the most accurate morphological traits for pelvic sex estimation for a long time [36]. They are often used as non-metric pelvic sexual dimorphism traits in sex estimation. Postmortem CT image data was used to establish virtual bone models for pelvic traits study [37]. The results showed that the established virtual-dry bone pairs ranged from moderate to almost perfectly agreed scores. The same research group then tested the non-metric traits VA, SC and MA, the other traits recommended by İşcan and Derrick [38], and Bruzek [39], as well as the metric traits sciatic notch (SN), composite arch (CA) and inferior pelvis (IP); the results suggested the non-metric traits methods were prone to errors due to the inherent subjectivity [40]. A recent study proposed that concerning the skeletal sample's unprofessionally preserved situation and carnivore scavenging, more traits including the ventral pubis (VP), dorsal pubis (DP), greater sciatic notch (GSN), pelvic inlet (PI), ischium, and acetabulum should be examined in pelvis related sex estimation. Based on the CT image scanning of the above 6 traits from 862 individuals, a CNN was developed for sex estimation. Results of this study showed that the CNN models trained with the VP, DP, GSN, and PI images achieved excellent results with all the prediction metrics over 0.9 [41].

Pelvic metric analysis usually includes angle, the measurements of distances between landmarks [42], the shape of pelvic bones, and reference line measurements [43]. Pelvic CT image data was obtained in the Malaysian population, and subpubic angles of pelvises on CT images were measured by Stratovan Checkpoint; the results showed that the subpubic angle in males was  $68.6^\circ \pm 7.6^\circ$  and in females was  $87.4^\circ \pm 6.5^\circ$  [44]. Similar studies have been done in Japanese [45] and Western Australian [46] populations to establish the population-specific sex estimation reference data. Portuguese population-specific osteometric models for the estimation of sex with 32 Euclidean distances between anatomic landmarks and 6 angles of the pelvis were performed by CT imaging method to present the web application and decision support system CADOES [47], the algorithms generated high-accuracy models ranging from 85% to 92% with only 3 variables; and from 85.33% to 97.33% with all 38 variables. The diagnose sexuelle probabiliste (DSP) which was developed by Murail, Brůžek [48] based on 10 measurements taken on the *os coxae*, and the ischio-pubic index (IPI) which was developed by Schultz [49] were studied on dry bones and CT generated 3D models to compare the measurement efficiency in real and virtual environments. Although some landmarks and measurements were not easy to assess, the study [50] pointed out that quantitative, measurements-based methods appeared to fare better in virtual environments than previously investigated non-metric CT imaging methods [51]. By seeking the supporting method to improve the estimation accuracy, the Fourier transform (FT) was used to analyze the shape of the subpubic line (SL) and the right greater sciatic notch area line (GSNAL) of the pelvis to estimate sex in postmortem CT images. The FT and CT combined methods showed an accuracy of over 98% in sex estimation [43].



**Figure 2.** Simulated human pelvis 3D reconstruction in the anterior view and right coxal bone 3D reconstruction in the oblique view with highlighted three sexual traits. (A) anterior view of simulated pelvis 3D reconstruction; arrow 1 indicates ventricle arc; arrow 2 indicates subpubic contour. (B) oblique view of simulated human right coxal bone 3D reconstruction; arrow 3 indicates medial aspect. The simulation was generated by using Sketchfab software. Original 3D model credits: Biological anthropologist Terrie Simmons-Ehrhardt's.

### 3.3. MRI and Sex Estimation

Head MRI and CT scans were performed on males and females in Northwest Indian adults with facial tissue thickness (FSTT) as the measurable parameter to estimate sex, both scans showed sexual dimorphism at most craniofacial landmarks with an accuracy rate of 96% and 85% in MRI scan and CT scan, respectively [52]. Head MRI

was performed on healthy living individuals to estimate sex by measuring the width, height, and depth of the maxillary sinus; the results showed that males had a statistically significant difference in both the volume and dimensions of their maxillary sinus compared to females and the left maxillary sinus volume had the highest percentage of sexual dimorphism in the studied population [53]. Skull thickness and scalp-to-cortical distance measurements on MRI images from the open-source Alzheimer's Disease Neuroimaging-Initiative [54] were studied to estimate sex, the results suggested male participants tended to have thicker skulls than female participants, albeit this difference was not statistically significant [55]. To the author's best knowledge, the application of the MRI imaging method to sex estimation based on pelvic structure has not been reported.

### 3.4. Ultrasound and Sex Estimation

Ultrasound was used with FSTT to estimate sex in Slovakia's population [56]. This study used a noninvasive General Electric LOGIQe R7 ultrasound equipment to quantify FSTT using 17 facial anthropometric landmarks. The findings showed that the zygomatic and eye regions in females and the mouth region in males had higher mean values of FSTT. There were 2 significant landmark FSTT differences between males and females, regardless of sex or BMI; but 12 landmarks showed changes when age and BMI were taken into account.

### 3.5. Surface Scanning and Sex Estimation

In an earlier study, the NextEngine Desktop 3D scanner was used by two operators with their respective protocols on 5 skulls to conduct surface area and volume measurements; the result showed the 3D laser scanners were valuable tools for measuring human skulls recovered from forensic and archaeological contexts [57]. Fresh cadaver heads were also scanned with different methods including 3D surface scanning, CT scanning and 3D stereo-photogrammetry system; the mean, standard deviation and reliability of 3D surface scanning on 21 soft tissue measurements suggested that it is sufficiently accurate and reliable in the fresh cadaver head measurements [58]. CT scanning and 3D surface scanning were performed on one skull to compare the reproducibility of these two methods; the result indicated that surface scanning yielded a higher reproducibility than CT scanning [59].

There is more evidence of 3D surface imaging application to sex estimation based on pelvic structure. To examine the accuracy of 3D surface scanning combined with CT imaging trained and tested CNN models, the same research group [41] used a handheld 3D surface scanner to scan 105 real pelvises and the accuracy of 3D surface scanning combined with CT imaging (focusing on VP, DP and GSN) trained and validated CNN models; the results obtained satisfactory accuracies above 95% on the VP and DP images compared to the GSN with 73.3% [60]. Two surface scanning devices, the laser scanner NextEngine 3D Ultra HD and the HP 3D Structured Light Scanner PRO S2 were used on *os coxae* to estimate the sex via DSP; although the structured light technology seemed to be more accurate than the laser technology due to it captures slightly more detail, there was not a significant effect on the estimate of the sex under optimal scanning settings [61]. A subsample of 39 pelvises was 3D surface scanned to compare observations with dry bone and CT data in the previously mentioned non-metric and metric study [40]; the 3D surface scan and CT comparison yielded a higher agreement than the 3D surface scan and dry bone comparison and CT and dry bone comparison.

## 4. Discussion

Radiology is used as a general documentation method for skeletal remains [62]. When performing the macroscopic examination and metric analysis to estimate the sex, it is practical to utilize X-ray image measurement software tools to facilitate the placing of landmarks on skeletal structures. In cases of fleshed remains, X-ray plays a critical role in visualizing landmarks and semi-landmarks that are not readily accessible in traditional metric and non-metric analyses [63]. Based on the advantages of landmark locating and metric analysis functions assisted by available processing software, sex estimation is often done by measuring the various parameters of the skull [12–14] and pelvis [15,16]. Metric analysis is the main focus of the X-ray imaging application to sex estimation based on skull and pelvic sexual dimorphism. The X-ray imaging skull sexual dimorphism studies suggest that parametric measurements by X-ray can effectively assist in specific populations and have the potential to provide the most accurate parameter(s) for sex estimation. In the X-ray imaging pelvic structure studies, although no convincing accuracy rate was found, the non-parametric textural analysis holds the potential to serve as an approach for sex estimation when the pelvic structure is highly fragmented. With the advantages and potentials of X-ray imaging addressed, conversely, the limitation of overlapping bony structures may lead to bias due to difficulties in finding accurate measurements on the two-dimensional (2D) cephalometric analysis [22] should be noticed as well.

Unlike the direct data capture function of digital radiography, CT scans take a sequence of radiographs from all possible angles, and data are combined to create cross-sectional images that can be stacked to create a 3D reconstruction of the scanned object using algorithms [62]. Thanks to the cross-section and 3D reconstruction functions of CT, it has become the most frequently used imaging method in sex estimation in the past decade. Non-metric examination and metric analysis are both common practices in the CT imaging application to sex estimation based on skull and pelvic structures. Due to the anatomical location, the 5 traits on the skull should be observed without any scalp or soft tissue interferences. When the skull is fleshed, the traditional macroscopic examination requires tissue removal which presents a risk of damaging the traits. The representative non-metric studies [17–19] imply that CT imaging provides excellent supplemental and alternative to traditional macroscopic examination when there is a high risk of damaging skull traits during the removal of soft tissue on the skull in sex estimation. This advantage provides the rationale to recommend CT as a supplemental method to the traditional macroscopic examination of skull traits at the current stage. From the metric analysis perspective, angle measurement approaches [21,22] convey that although the glabella and mandible are considered sexually dimorphic, the metric analysis of the angles on the individual traits or bones, especially when the structure is incomplete may provide a reference but not a convincing accuracy rate for sex estimation. The metric analyses based on the distances between landmarks [23–28,32] indicate the advantages including the ability to perform inter-landmark distance measurements as they are difficult to access in traditional metric analysis and 2D cephalometric analysis; the inter-landmark distance measurement ability of CT complements the traditional metric examination and may be adopted as a complementary method in current practice. The innovative metric analyses [29–31] based on the exocranial mesh studies on cranial form and color scales provide the computed sex examination ability on the whole cranial surface, as well as separate structures when the internal or other cranial structures are not available in multiple contemporary populations. Sex estimation could be accomplished even on partial cranial remains when the skull is fragmented or not fully discovered as there are population-specific sexual dimorphic parameters identified; the possibility of using CNN in sex estimation casework when there is a disagreement by traditional methods; the potential of utilizing existing CT imaging data to establish population-specific sexual dimorphism reference data. Given the reality that most metric analysis references were established on the basis of specific populations, for example, U.S. Whites, U.S. Blacks, medieval Nubians, and Arikara Native Americans [64], the population-inclusive sex estimation [34,35] provides an idea for sex estimation when the ancestry is unclear or unable to be estimated.

The non-metric studies [37,40,41] in pelvises by CT imaging method put forward the following: pelvic traits study that solely depends on CT imaging data does not provide a convincing accuracy rate in sex estimation; however, when more traits from the various locations of a pelvis are included in the scanning and CNN is employed, the power of CT imaging in sex estimation is assuring. From the metric analysis perspective, considering the subpubic angle is a reliable metric parameter in sex estimation [20,36], the subpubic angle CT imaging metric analyses [44–46] imply that clinical images in a specific population are excellent sources for population-specific subpubic angle sex estimation reference data establishment. Taken the recent representative distance measurement metric studies [43,47,50,51] together, there is no strong evidence to support that metric analysis solely assisted by CT has an acceptable accuracy rate in sex estimation, but when it is used with FT of the reference line measurements, the accuracy rate is encouraging. Although the role of CT imaging in sex estimation encompasses obvious advantages, some considerations are present. Most studies especially the population-specific reference data establishment adopted existing living individuals' images, which may not be suitable for metric analysis in postmortem sex estimation. Human remains lack soft tissue, which is different from living individuals' body environment composition. This disparity suggests data acquired from existing living individuals' images may not be applied to sex estimation directly [33]. In addition, the limited access to facilities equipped with required CT imaging technology and the relatively high expense of CT scanning may be prohibitive for many practitioners, and access to specialist computer software and familiarity in working with 3D datasets are prerequisites for working with CT images [62].

MRI utilizes a strong magnet to pass radio waves through the body, whereupon the protons respond to the energy and produce detailed images of bodily structures including blood vessels, nerves, and soft tissues [65]. Among its functions, MRI presents a means for quantitative evaluation of the volume and dimensions of organ/structure soft tissue and its components [66,67]. MRI also accommodates the need for the non-radiation necessity for forensic purposes on living persons [3]. The application of this specific imaging technology is more common in cases involving living. The representative studies [52,53,55] on skulls regarding sex estimation were based on living individuals' MRI images. Another non-invasive and non-radiation imaging technique that utilizes the soft tissue characteristic and applies to living individuals' sex estimation is ultrasound [68]. Although ultrasound waves do not travel well through air or bone which suggests it is not a common method of sex estimation on human remains when it is incorporated with FSTT [56], it



provides an excellent solution for age estimation in living individuals based on facial tissue thickness, especially when MRI is difficult to access. In fact, FSTT was utilized with CT imaging [69] to serve the same role before it was employed with MRI or ultrasound.

Surface scanning is also a non-invasive and non-ionizing imaging method to capture the color, shape, texture and volume information of a 3D object. Surface scanners can be handheld or stationary. They use active light projections to render complex geometry, sharp corners and edges and other morphological characteristics for 3D images or models production of the object being scanned [70]. With the features of low cost, portability, surface texture captions, and reproducibility, surface scanning manifests its application feasibility in the skull [71] and pelvis [60] reconstructions which lay the foundation for its application to sex estimation. Despite the fact that relevant studies [57–59] on 3D surface scanning of skulls do not reflect its specific application to sex estimation, its strong metric analysis ability and high reproducibility advocate a high potential of this method to serve as an optional method for sex estimation based on skull structure when the complex CT imaging facility is not available. Other evidence [40,60,61] demonstrates the feasibility of using 3D surface imaging in sex estimation based on the pelvic structure, with high accuracy when employing CNN in the non-metric examination. At the current stage, only the reliability of the 3D surface scanning method in the metric analysis is promising due to the lack of reported accuracy. Also, its difficulty in scanning and collecting the internal morphometry and density of bones with an irregular morphology [72] is another limitation that should be considered in the application.

In forensic anthropology, the often-encountered body conditions are decomposed or skeletonized and they do not reflect the soft tissue texture, volume and many other features as in living individuals. Different from other imaging techniques that work well with human remains, MRI and ultrasound hold soft tissue-oriented functions. Also thanks to their ionizing radiation-free feature, MRI and ultrasound serve their role in living individuals' sex estimation other than in the postmortem context. However, while they are useful tools for sex estimation especially when FSTT is employed, traditional methods such as DNA analysis should always be used to confirm the estimation.

## 5. Conclusions and Prospects

The application of forensic imaging to sex estimation research and practice has grown dramatically in recent years. Common forensic imaging methods are applied to sex estimation with CT being the most favored in the last decade. Although extensive advantages have been identified, the adjunct role of forensic imaging to traditional sex examination carried out by forensic anthropologists through non-metric macroscopic examination and metric analysis cannot be changed due to its limiting factors at the current stage. Therefore, the rationale for adopting the mature imaging method CT as a supplemental method of traditional morphologically-based or mathematically-based scientific manner in ANSI/ASB Standard 090 is adequate. The development of neural network architectures such as CNN with high performance in computer vision-related tasks is the most encouraging path to unlock the potential of forensic imaging in sex estimation. Considering some limiting factors such as the large data set requirement for CNN establishment, and forensic anthropologists' limited access to imaging facilities, a resource and data-sharing program including facility, research, training and funding resources can be initiated to coordinate and optimize resources and data utilization. In addition, open forensic imaging and anthropology resources such as the New Mexico Decedent Image Database (NMDID) [73], the Subadult Virtual Anthropology Database (SVAD) [74], the American Association of Orthodontists Foundation (AAOF) Database [75] can be accessed for sex estimation studies by requests or direct downloads. Moreover, the exploration and adoption of peer-reviewed web-based graphical user interfaces such as (hu)MANid [76] serve as a complementary tool to assist in sex estimation after the metric and morphoscopic data are obtained by dry bone forensic imaging data; the interfaces potentially provide researchers with the foundation to establish a similar tool that incorporates statistical modification to estimate sex from non-dried bone imaging data.

## Acknowledgments

I would like to thank 3D Biological Anthropologist Terrie Simmons-Ehrhardt for the Sketchfab 3D models and technical support. I also thank all reviewers for their helpful comments on the manuscript.

## Ethics Statement

This article does not contain any studies with human participants or animals performed by the author.

## Informed Consent Statement

Not applicable.

## Funding

This research received no external funding.

## Declaration of Competing Interest

The authors declare that they have no known competing financial interests or personal relationships that could have appeared to influence the work reported in this paper.

## References

- Grabherr S. Forensic imaging. *Forensic Sci. Res.* **2017**, *2*, 51.
- Bolliger SA, Thali MJ. Imaging and virtual autopsy: Looking back and forward. *Philos. Trans. Royal Soc. B Biol. Sci.* **2015**, *370*, 1674.
- Grabherr S, Egger C, Vilarino R, Campana L, Jotterand M, Dedouit F. Modern post-mortem imaging: an update on recent developments. *Forensic Sci. Res.* **2017**, *2*, 52–64.
- Zhang M. Forensic imaging: a powerful tool in modern forensic investigation. *Forensic Sci. Res.* **2022**, *7*, 385–392.
- Zhang M, Atta-obeng E. Engaging students in forensic anthropology learning: A comprehensive pedagogical model. *J. Forensic Sci. Educ.* **2023**, *5*, 2.
- Austin D, King RE. The Biological Profile of Unidentified Human Remains in a Forensic Context. *Acad. Forensic Pathol.* **2016**, *6*, 370–390.
- Krishan K, Chatterjee PM, Kanchan T, Kaur S, Baryah N, Singh RK. A review of sex estimation techniques during examination of skeletal remains in forensic anthropology casework. *Forensic Sci. Int.* **2016**, *261*, 165.
- AAFS Standards Board. Standard for Sex Estimation in Forensic Anthropology. 2019. Available online: [www.asbstandardsboard.org](http://www.asbstandardsboard.org) (accessed on 11 May 2024).
- Garvin HM. Adult sex estimation from cranial morphological traits. In *Sex Estimation of the Human Skeleton: History, Methods, and Emerging Techniques*; Academic Press: London, UK, 2020.
- Robles M, Carew RM, Rando C, Nakhaeizadeh S, Morgan RM. Sex estimation from virtual models: exploring the potential of stereolithographic 3D crania models for morphoscopic trait scoring. *Forensic Sci. Res.* **2023**, *8*, 123–132.
- Sketchfab. Available online: <https://sketchfab.com/search?type=models> (accessed on 18 April 2024)
- Poongodi V, Kanmani R, Anandi MS, Krithika CL, Kannan A, Raghuram PH. Prediction of age and gender using digital radiographic method: A retrospective study. *J. Pharm. Bioallied. Sci.* **2015**, *7*, S504–S508.
- González-Colmenares G, Sanabria Medina C, Rojas-Sánchez MP, León K, Malpud A. Sex estimation from skull base radiographs in a contemporary Colombian population. *J. Forensic Leg. Med.* **2019**, *62*, 77–81.
- Ningtyas AH, Widyaningrum R, Shantiningsih RR, Yanuaryska RD. Sex estimation using angular measurements of nasion, sella, and glabella on lateral cephalogram among Indonesian adults in Yogyakarta. *Egypt J. Forensic Sci.* **2023**, *13*, 48.
- Varzandeh C, Akhlaghi M, Farahani VV, Mousavi M, Jashni K, Yousefinejad S. The Diagnostic Value of Anthropometric Characteristics of Ilium for Sex Estimation Using Pelvic Radiographs. *Int. J. Med. Toxicol. Forensic Med.* **2019**, *9*, 1–10.
- Kamiński P, Nurzynska K, Kwiecień J, Obuchowicz R, Piórkowski A, Pociask E, et al. Sex Differentiation of Trabecular Bone Structure Based on Textural Analysis of Pelvic Radiographs. *J. Clin. Med.* **2014**, *13*, 1904.
- Dereli AK, Zeybek V, Sagtas E, Senol H, Ozgul HA, Acar K. Sex determination with morphological characteristics of the skull by using 3D modeling techniques in computerized tomography. *Forensic Sci. Med. Pathol.* **2018**, *14*, 450–459.
- Bertsatos A, Chovalopoulou ME, Brůžek J, Bejdová Š. Advanced procedures for skull sex estimation using sexually dimorphic morphometric features. *Int. J. Legal. Med.* **2020**, *14*, 1927–1937.
- Yaşar B, Sağır M. Testing of morphological sex estimation traits with a sex-known collection: Ottoman period skulls. *Int. J. Osteoarchaeol.* **2023**, *33*, 1042–1051.
- Christensen AM, Passalacqua NV, Bartelink EJ. *Forensic Anthropology: Current Methods and Practice*; Academic Press: London, UK, 2019.
- Tunis TS, Sarig R, Cohen H, Medlej B, Peled N, May H. Sex estimation using computed tomography of the mandible. *Int. J. Legal. Med.* **2017**, *131*, 1691–1700.
- Albalawi A, Alam M, Vundavalli S, Ganji K, Patil S. Mandible: An indicator for sex determination—A three-dimensional cone-beam computed tomography study. *Contemp. Clin. Dent.* **2019**, *10*, 69–73.
- Zaafraane M, Khelil MB, Naccache I, Ezzedine E, Savall F, Telmon N, et al. Sex determination of a Tunisian population by CT scan analysis of the skull. *Int. J. Legal. Med.* **2018**, *132*, 853–862.



24. Kramer NA, Lopez-Capp TT, Michel-Crosato E, Biazevic MGH. Sex estimation from the mastoid process using Micro-CT among Brazilians: Discriminant analysis and ROC curve analysis. *J. Forensic Radiol. Imag.* **2018**, *14*, 1–7.
25. Mehta M, Saini V, Nath S, Menon SK. CT scan images for sex discrimination - a preliminary study on Gujarati population. *J. Forensic Radiol. Imag.* **2015**, *3*, 43–48.
26. García-Donas JG, Ors S, Inci E, Kranioti E, Ekizoglu O, Moghaddam N, et al. Sex estimation in a Turkish population using Purkait's triangle: a virtual approach by 3-dimensional computed tomography (3D-CT). *Forensic Sci. Res.* **2022**, *7*, 97–105.
27. Čechová M, Dupej J, Brůžek J, Bejdová Š, Horák M, Velemínská J. Sex estimation using external morphology of the frontal bone and frontal sinuses in a contemporary Czech population. *Int. J. Legal. Med.* **2019**, *133*, 1285–1294.
28. Mahakkanukrauh P, Sinthubua A, Prasitwattanaseree S, Ruengdit S, Singuwan P, Praneatpolgrang S, et al. Craniometric study for sex determination in a Thai population. *Anat. Cell Biol.* **2015**, *48*, 275.
29. Musilová B, Dupej J, Velemínská J, Chaumoitre K, Bruzek J. Exocranial surfaces for sex assessment of the human cranium. *Forensic Sci. Int.* **2016**, *269*, 70–77.
30. Musilová B, Dupej J, Brůžek J, Bejdová Š, Velemínská J. Sex and ancestry related differences between two Central European populations determined using exocranial meshes. *Forensic Sci. Int.* **2019**, *297*, 364–369.
31. Meinerová T, Šutoová D, Brukner Havelková P, Velemínská J, Dupej J, Bejdová Š. How reliable is the application of the sex classifier based on exocranial surface (Musilová et al., 2016) for geographically and temporally distant skull series. *Forensic Sci. Int.* **2023**, *352*, 111850.
32. Bewes J, Low A, Morphett A, Pate FD, Henneberg M. Artificial intelligence for sex determination of skeletal remains: Application of a deep learning artificial neural network to human skulls. *J. Forensic Leg. Med.* **2019**, *62*, 40–43.
33. Kondou H, Morohashi R, Kimura S, Idota N, Matsunari R, Ichioka H, et al. Artificial intelligence-based forensic sex determination of East Asian cadavers from skull morphology. *Sci. Rep.* **2023**, *13*, 21026.
34. Tallman S. Cranial Nonmetric Sexual Dimorphism and Sex Estimation in East and Southeast Asian Individuals. *Forensic Anthropol.* **2019**, *2*, 204–221.
35. Kelley SR, Tallman SD. Population-Inclusive Assigned-Sex-at-Birth Estimation from Skull Computed Tomography Scans. *Forensic Sci.* **2022**, *2*, 24.
36. Klaes AR. Sex estimation using pelvis morphology. In *Sex Estimation of the Human Skeleton: History, Methods, and Emerging Techniques*; Academic Press: London, UK, 2020.
37. Colman KL, van der Merwe AE, Stull KE, Dobbe JG, Streekstra GJ, Van Rijn RR, et al. The accuracy of 3D virtual bone models of the pelvis for morphological sex estimation. *Int. J. Legal. Med.* **2019**, *133*, 1853–1860.
38. Işcan MY, Derrick K. Determination of Sex from the Sacroiliac Joint: A Visual Assessment Technique. *Fla. Sci.* **1984**, *47*, 2.
39. Bruzek J. A method for visual determination of sex, using the human hip bone. *Am. J. Phys. Anthropol.* **2002**, *117*, 157–168.
40. Braun S, Schwendener N, Kanz F, Lösch S, Milella M. What we see is what we touch? Sex estimation on the pelvis in virtual anthropology. *Int. J. Legal. Med.* **2023**, *137*, 1839–1852.
41. Cao Y, Ma Y, Yang X, Xiong J, Wang Y, Zhang JH, et al. Use of deep learning in forensic sex estimation of virtual pelvic models from the Han population. *Forensic Sci. Res.* **2022**, *7*, 540–549.
42. Baca K, Bridge B, Snow M. Three-dimensional geometric morphometric sex determination of the whole and modeled fragmentary human pubic bone. *PLoS ONE* **2022**, *17*, 0265754.
43. Hayashizaki Y, Usui A, Hosokai Y, Sakai J, Funayama M. Sex determination of the pelvis using Fourier analysis of postmortem CT images. *Forensic Sci. Int.* **2015**, *246*, 122.
44. Ali SHM, Omar N, Shafie MS, Ismail NAN, Hadi H, Nor FM. Sex estimation using subpubic angle from reconstructed three-dimensional computed tomography pelvic model in a contemporary Malaysian population. *Anat. Cell Biol.* **2020**, *53*, 27.
45. Torimitsu S, Makino Y, Saitoh H, Sakuma A, Ishii N, Yajima D, et al. Morphometric analysis of sex differences in contemporary Japanese pelvises using multidetector computed tomography. *Forensic Sci. Int.* **2015**, *257*, 530.
46. Franklin D, Cardini A, Flavel A, Marks MK. Morphometric analysis of pelvic sexual dimorphism in a contemporary Western Australian population. *Int. J. Legal. Med.* **2014**, *128*, 861–872.
47. d'Oliveira Coelho J, Curate F. CADOES: An interactive machine-learning approach for sex estimation with the pelvis. *Forensic Sci. Int.* **2019**, *302*, 109873.
48. Murail P, Bruzek J, Houët F, Cunha E. DSP: A tool for probabilistic sex diagnosis using worldwide variability in hip-bone measurements. *Bull. Mem. Soc. Anthropol. Paris* **2005**, *17*, 167–176.
49. Schultz A. The skeleton of the trunk and limbs of higher primates. *Hum. Biol.* **1930**, *2*, 303–438.
50. Abegg C, Hoxha F, Campana L, Ekizoglu O, Schranz S, Egger C, et al. Measuring pelvises in 3D surface scans and in MDCT generated virtual environment: Considerations for applications in the forensic context. *Forensic Sci. Int.* **2023**, *352*, 111813.
51. Abegg C, Balbo I, Dominguez A, Grabherr S, Campana L, Moghaddam N. Virtual anthropology: a preliminary test of macroscopic observation versus 3D surface scans and computed tomography (CT) scans. *Forensic Sci. Res.* **2021**, *6*, 34–41.
52. Kaur K, Sehrawat JS, Bahadur R. Sex dependent variations in craniofacial soft-tissue thicknesses estimated from MRI and CT scans: A pilot study based on Northwest Indian subjects. *Int. J. Diagn. Imag.* **2017**, *4*, 47.

53. Rani SU, Rao GV, Kumar DR, Sravya T, Sivaranjani Y, Kumar MP. Age and gender assessment through three-dimensional morphometric analysis of maxillary sinus using magnetic resonance imaging. *J. Forensic Dent. Sci.* **2017**, *9*, 46.
54. Weber CJ, Carrillo MC, Jagust W, Jack CR Jr, Shaw LM, Trojanowski JQ, et al. The Worldwide Alzheimer's Disease Neuroimaging Initiative: ADNI-3 updates and global perspectives. *Alzheimer's Dement. Transl. Res. Clin. Interv.* **2021**, *7*, e12226.
55. Zhang J, Treyer V, Sun J, Zhang C, Gietl A, Hock C, et al. Automatic analysis of skull thickness, scalp-to-cortex distance and association with age and sex in cognitively normal elderly. *Brain Stimul.* **2023**, *16*, 653–656.
56. Švábová P, Matláková M, Beňuš R, Chovancová M, Masnicová S. The relationship between biological parameters and facial soft tissue thickness measured by ultrasound and its forensic implications. *Med. Sci. Law* **2024**, *64*, 23–31.
57. Sholts SBS, Wärmländer SKT, Flores LM, Miller KWP, Walker PL. Variation in the measurement of cranial volume and surface area using 3D laser scanning technology. *J. Forensic Sci.* **2010**, *55*, 871–876.
58. Fourie Z, Damstra J, Gerrits PO, Ren Y. Evaluation of anthropometric accuracy and reliability using different three-dimensional scanning systems. *Forensic Sci. Int.* **2011**, *207*, 127–134.
59. Fahrni S, Campana L, Dominguez A, Uldin T, Dedouit F, Delémont O, et al. CT-scan vs. 3D surface scanning of a skull: first considerations regarding reproducibility issues. *Forensic Sci. Res.* **2017**, *2*, 93–99.
60. Cao Y, Ma Y, Vieira DN, Guo Y, Wang Y, Deng K, et al. A potential method for sex estimation of human skeletons using deep learning and three-dimensional surface scanning. *Int. J. Legal. Med.* **2021**, *135*, 2409–2421.
61. Kotěrová A, Králík V, Rmoutilová R, Friedl L, Růžicka P, Velemínská J, et al. Impact of 3D surface scanning protocols on the Os coxae digital data: Implications for sex and age-at-death assessment. *J. Forensic Leg. Med.* **2019**, *68*, 101866.
62. Garvin HM, Stock MK. The Utility of Advanced Imaging in Forensic Anthropology. *Acad. Forensic Pathol.* **2016**, *6*, 499–516.
63. Franklin D, Swift L, Flavel A. 'Virtual anthropology' and radiographic imaging in the Forensic Medical Sciences. *Egypt J. Forensic Sci.* **2016**, *6*, 31–43.
64. Garvin HM, Sholts SB, Mosca LA. Sexual dimorphism in human cranial trait scores: Effects of population, age, and body size. *Am. J. Phys. Anthropol.* **2014**, *154*, 22502.
65. Pool JL. Magnetic resonance imaging. *Biomed. Instrum. Technol.* **2002**, *36*, 341–346.
66. Goldstein JM, Seidman LJ, Horton NJ, Makris N, Kennedy DN, Caviness VS, et al. Normal sexual dimorphism of the adult human brain assessed by in vivo magnetic resonance imaging. *Cerebral. Cortex* **2001**, *11*, 490–497.
67. Yasar Teke H, Ünlütürk Ö, Günaydin E, Duran S, Özsoy S. Determining gender by taking measurements from magnetic resonance images of the patella. *J. Forensic Leg. Med.* **2018**, *58*, 87–92.
68. Möbius D, Fitzek A, Hammer N, Heinemann A, Ron A, Schädler J, et al. Ultrasound in legal medicine—A missed opportunity or simply too late? A narrative review of ultrasonic applications in forensic contexts. *Int. J. Legal. Med.* **2021**, *135*, 2363–2383.
69. Panenková P, Beňuš R, Masnicová S, Obertová Z, Grunt J. Facial soft tissue thicknesses of the mid-face for Slovak population. *Forensic Sci. Int.* **2012**, *220*, 293.e1–e6.
70. Straub J, Kading B, Mohammad A, Kerlin S. Characterization of a Large, Low-Cost 3D Scanner. *Technologies* **2015**, *3*, 19–36.
71. Cho RY, Byun SH, Yi SM, Ahn HJ, Nam YS, Park IY, et al. Comparative Analysis of Three Facial Scanners for Creating Digital Twins by Focusing on the Difference in Scanning Method. *Bioengineering* **2023**, *10*, 545.
72. Baban MT A, Mohammad DN. The Accuracy of Sex Identification Using CBCT Morphometric Measurements of the Mandible, with Different Machine-Learning Algorithms—A Retrospective Study. *Diagnostics* **2023**, *13*, 2342.
73. New Mexico Decedent Image Database (NMDID). Available online: <https://nmdid.unm.edu/#> (accessed on 12 December 2023).
74. Subadult Virtual Anthropology Database (SVAD). Available online: <https://www.unr.edu/anthropology/research-and-facilities/subadult-database#> (accessed on 12 December 2023).
75. American Association of Orthodontists Foundation (AAOF) Database. Available online: [https://www.aaoflegacycollection.org/aaof\\_home.html](https://www.aaoflegacycollection.org/aaof_home.html) (accessed on 12 April 2024).
76. (hu)MANid. Available online: <https://anthropologyapps.shinyapps.io/humanid/> (accessed on 12 April 2024).